

Significance of Various Diagnostic Methods for the Detection of Helicobacter Pylori Infection

Rasheed Ahmed Soomro, Muhammad Kaleem, Riaz Ahmed Qazi, Faisal Irshad,
Mehwish Zafar, Moin-ul-Islam

ABSTRACT

OBJECTIVE: To determine the diagnostic significance of Helicobacter pylori (H. pylori) infection by histological examination of tissues and rapid Immunochromatographic assay from stool samples.

METHODOLOGY: This retrospective comparative study was performed in the Departments of Pathology and Medicine, Suleman Roshan Medical College Tandoadam, from August to December 2020, on one hundred cases collected by consecutive nonprobability technique, of any sex and age, having a clinical opinion of H pylori disease. Samples were collected, and gastric endoscopic biopsies were performed in all cases in the department of Medicine and shifted to the Pathology department for registration and processing. The rapid Immunochromatographic assay of the same patients was also performed to isolate H. pylori from faecal samples. All the data collected were statistically analyzed using SPSS 20, and the results were tabulated.

RESULTS: On histological examination, H. pylori bacilli were detected in 90 (90%) patients, of which the male was 52(57.7 %). The age ranges from 14 - 85 years, with a mean of 47.9. The histopathologically positive cases were compared with stool antigen, and H. pylori antigen in stool were isolated on immunochromatography technique in 48 (48%) subjects. The sensitivity and specificity of stool antigen were 52.74% and 90%, respectively, and the P-value was 0.011.

CONCLUSION: H. pylori positivity is highly significant in histological examination of endoscopic gastric biopsies and may be identified by stool analysis as seen in this study which is noninvasive, most straightforward and has low expenses.

KEY WORDS: H. pylori, Endoscopic Gastric Biopsies, Histological Examination, Stool Antigen

This article may be cited as: Soomro RA, Kaleem M, Qazi RA, Irshad F, Zafar M, Moin-ul-Islam. Significance of Various Diagnostic Methods for the Detection of Helicobacter Pylori Infection. J Liaquat Uni Med Health Sci. 2022;21(02):126-30. doi: 10.22442/jlumhs.2022.00916. Epub 2022 May 10.

INTRODUCTION

Significant attention occurs in the learning of gastric microbiology after detecting spiral-like organisms 'Campylobacter' isolated from the specimens of biopsy from gastric antrum¹. The gastric mucosa harbour colonies of H. pylori in almost every fourth of the adult population². It is documented that there was uncertainty regarding the anticipated part of H. pylori infection in the causation of chronic active gastritis and peptic ulcer disease³.

H. pylori organisms are worldwide concerned in the pathogenesis of acid peptic disease⁴; there is universal dissemination along with an elevated frequency in unindustrialized countries within elderly persons, and is fundamental with chronic active antral gastritis and is highly linked with duodenal and gastric ulcers⁵. It may persist in the acidic gastric setting by the enzyme urease, which transforms urea into

ammonia and carbon dioxide, empowering it to neutralize the acid in its close environment⁶.

It is considered that the H. pylori infection is prevalent throughout the world, but about 70% of sufferers are asymptomatic. About 50% of symptomatic cases comprise peptic ulcer disease, lymphoproliferative disorders, and gastric carcinoma. The involved patients suffer from duodenal ulcers, while other shows develop gastric ulceration and have altered frequency of infection in unindustrialized and industrialized nations⁷. Various invasive and noninvasive methods nowadays exist to detect H. pylori infection⁸. The invasive procedure includes culture, microscopic evaluation, urease testing and endoscopic biopsy from suspected areas⁹.

The invasive procedures are tiresome and time-consuming and need a specimen process resulting in patient discomfort¹⁰. H. pylori are a delicate bacterium and so smashed during transportation¹¹. The noninvasive methods are urea breath test needs ingestion of carbon isotope urea derivates⁴, and recognition of serum antibodies to H. pylori serologically¹².

Received: 13-09-2021
Revised: 16-03-2022
Accepted: 19-04-2022
Published Online: 10-05-2022

METHODOLOGY

This retrospective comparative work was performed in the Pathology and Medicine department, Suleman Roshan Medical College Tando Adam, from August to December 2020, on one hundred cases collected by consecutive nonprobability technique, having a clinical opinion of H pylori infection. Patients included were cases of all ages and sex having symptoms of dyspepsia or clinically suspected cases of H. pylori associated gastritis. Cases having complete denudated or ulcerated mucosa or samples having autolytic effects. Patients with a history of using non-steroidal anti-inflammatory drugs (NSAIDs) or extirpate treatment were omitted from the study.

A structured proforma was formatted for the study, collecting all the demographic and clinical information. Endoscopists also noted clinical judgments and appropriate data of all the cases and patients. The current study compares the following approaches for recognizing H. pylori infection with specificity and sensitivity.

1. Gastric endoscopic, microscopic examination by H & E and Giemsa stain
2. Rapid Immunochromatographic assay: isolation of H. pylori antigen from faecal material

RESULTS

Among 100 cases of gastric biopsy, H. pylori bacilli were detected microscopically in 90(90%) cases while examined under a microscope using H & E and Giemsa stains. These comprise 52(57.7 %) males and 38(42.3 %) females. The age of the study population ranged from 14 to 85 years, with a mean of 47.9 (Table I).

The fresh faecal specimen was obtained from 100 cases in a sterilized container; the H. pylori antigen

was isolated by immunochromatography and confirmed in 48(48%) subjects. The stool antigen was detected in 28(58.3%) males (Table II). The specificity and sensitivity of stool antigen were 52.74% and 90%, respectively and the P-value detected was 0.011.

Table III shows the results of 100 gastric biopsies on Stool Analysis to detect H pylori. Among 90 positive cases of H pylori, 47(52.22%) cases showed HpSA positive, while 43(47.78%) showed HpSA negative. Out of 10 negative cases of H pylori, 01(10.0%) cases showed HpSA positive, while 09 (90%) cases showed HpSA negative.

Table IV shows the Sensitivity and Specificity of the H pylori stool antigen test. The sensitivity of the H pylori antigen test was found to be 52.22%, while specificity was found to be 90%.

TABLE III: RESULTS OF 100 GASTRIC BIOPSIES ON STOOL ANALYSIS FOR ISOLATION OF H. PYLORI

Gastric biopsies on H&E & Giemsa stain	No of cases	Pos-itive	Percent (%)	Neg-ative	Percent (%)
HpSA positive	90	47	52.22%	43	47.78%
HpSA Negative	10	01	10.00%	09	90%

TABLE IV: SENSITIVITY AND SPECIFICITY OF H. PYLORI STOOL ANTIGEN TEST

HpSA	Positive	Negative
Positive	(a) 47	(b) 01
Negative	(c) 43	(d) 09

$Sensitivity = a/(a+c) \times 100 = 52.22\%$ $Specificity = d/(d+b) \times 100 = 90\%$

TABLE I: ANALYSIS OF GASTRIC BIOPSIES REGARDING AGE & SEX

Gastric biopsies Analysis	Male				Female				Grand Total
	14-32	33-64	65-85	Total	14-32	33-64	65-85	Total	
Age Group	14-32	33-64	65-85	Total	14-32	33-64	65-85	Total	
Positive +++	02	03	00	05	01	02	00	03	08
Positive ++	01	02	00	03	01	04	00	05	08
Positive +	20	21	03	52	08	22	00	38	74
Negative	00	04	00	04	02	04	00	06	10
Total	23	30	03	56	12	32	00	44	100

+=Low, ++=Medium, +++=Higher

TABLE II: H. PYLORI STOOL ANTIGEN TEST WITH AGE AND SEX (n=100)

H. pylori Stool Antigen	Male				Female				Grand Total
	14-32	33-64	65-85	Total	14-32	33-64	65-85	Total	
Age Group	14-32	33-64	65-85	Total	14-32	33-64	65-85	Total	
Positive	11	16	1	28	6	14	0	20	48
Negative	12	14	2	28	6	18	0	24	52
Total	23	30	3	56	12	32	0	44	100

FIGURE I: MICROPHOTOGRAPH SHOWING HELICOBACTER PYLORI, (ARROW) ON H & E STAIN

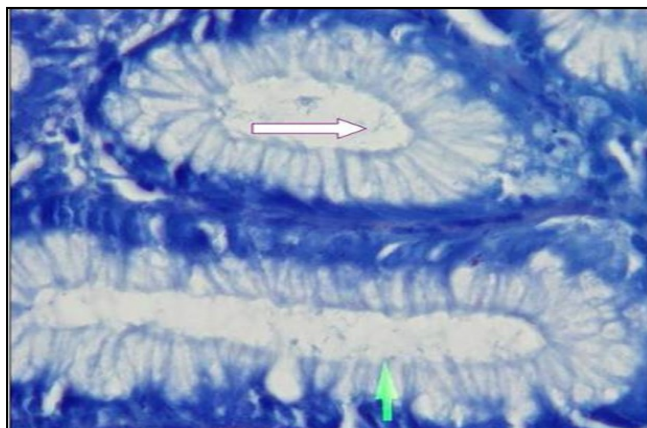
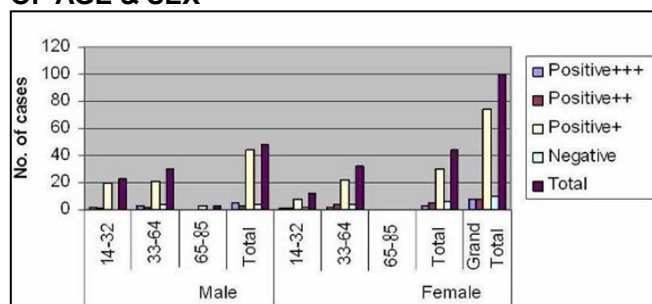


FIGURE II: CHROMATOGRAPHS SHOW STOOL ANTIGEN POSITIVE BY RAPID IMMUNOCHROMATOGRAPHY



GRAPH: GASTRIC BIOPSY SAMPLES IN TERMS OF AGE & SEX



DISCUSSION

Over the past 52 years of the history of endoscopy, it has been broadly merged to identify upper GIT conditions¹³. The main explanation for the execution of endoscopic examination is to detect the underlying ulcer disease. The noninvasive investigations for *H. pylori* have proved to be a valuable prognosticator for endoscopic judgment in managing dyspepsia¹⁴. For the isolation of *H. pylori*, the culture is thought to be a gold standard technique. However, it focuses on inaccuracy in the storage and handling of the sample, so histological testing is believed to be the gold standard in identifying *H. pylori* contamination. The biopsy process depends on inaccuracy as the infection is in patches and afterwards incompletely effective abolition, low-level contamination can be

missed on biopsy¹⁵.

In our study, out of 100 cases, 90 (90%) cases of gastric biopsies were labelled positive for *H. pylori* organisms, and the remaining 10 (10%) cases were negative; this finding attested to the results of previous national and international studies which detected 93.8% and 90% of positive cases respectively^{16,17}, while one national study revealed a result of 64% due to unknown reason¹⁵. Another study conducted on endoscopic biopsies of 63 patients showed 87% positive cases for *H. pylori* on Giemsa stain¹⁸.

Although our study coincides with the research mentioned above, more significant and specific than these, it may be due to more expertise of gastroenterologists performing endoscopic procedures, locating the proper area for a biopsy on one side and education of patients to approach gastroenterologists for their better and early treatment on other side.

In our research, among 90 positive cases, 52 (57.7%) were male. There is a slight variation of results in other studies, like other workers who found 52.2% and 66.6% male cases in their studies^{16,17}. The reason for the involvement of more male populations requires further research.

Endoscopic biopsy for histopathological examination is essential for identifying *H. pylori* organisms. Although it is an invasive, expensive, and inconvenient procedure, it is still considered and proved the gold standard technique for isolating *H. pylori* infection.

In our study, stool examination was performed on 100 cases to recognize the antigen. Among 90 (90%) histopathologically positive cases, 47 (52.22%) were positive on the immunochromatography process. Among ten histologically negative cases for infection, we confirm only 01 cases were positive, and 09 samples were negative. The positivity may be due to selecting an improper site for biopsy by an endoscopist; in contrast, a high positivity ratio of 60% and 79.59% is documented in the literature^{19,20}. The lesser number of positive subjects in our study may be because of the inadequate number of antigens in the stools.

CONCLUSION

In our study, *H. pylori* positivity is highly significant in the histological examination of endoscopic biopsies on H&E and Giemsa Stains. It is still to be proved a more reliable and gold standard method for diagnosing *H. pylori*. It will be more helpful if gastric biopsies should be taken from the proper site and multiple biopsies by endoscopists as gastritis is a patchy inflammatory disease. In this position, the case may be detected by serum or stool analysis, which are noninvasive, most straightforward and least expensive methods.

Ethical Permission: Suleman Roshan Medical College Tando Adam Sindh approval letter dated 11-08-2021.

Conflict of Interest: The authors have no conflicts of interest to declare.

Financial Disclosure / Grant Approval: There was no funding agency used for this research.

DATA SHARING STATEMENT: The data supporting this study's findings are available on request from the corresponding author. The data are not publicly available due to privacy or ethical restrictions.

AUTHOR CONTRIBUTIONS

Soomro RA: Main idea and conception

Kaleem M: Collection and acquisition of data, analysis of data

Qazi RA: Design, interpretation of data

Irshad F: Analysis and interpretation of results

Zafar M: Compilation and finalizing of manuscript

UI-Islam M: Critical review of manuscript, reference collection

REFERENCES

1. Sabbagh P, Mohammadnia-Afrouzi M, Javanian M, Babazadeh A, Koppolu V, Vasigala VR et al. Diagnostic methods for Helicobacter pylori infection: ideals, options, and limitations. *Euro J Clin Microbio Infect Dis*. 2019; 38(1): 55-66. doi: 10.1007/s10096-018-3414-4.
2. Karkhah A, Ebrahimpour S, Rostamtabar M, Koppolu V, Darvish S, Krishna Rekha et al. Helicobacter pylori evasion strategies of the host innate and adaptive immune responses to survive and develop gastrointestinal disease. *Microbiol Res*. 2019; 218: 49-57. doi: 10.1016/j.micres.2018.09.011.
3. Forbes KJ, Fang Z, Pennington TH. Allelic variation of the Helicobacter pylori flagellin genes flaA and flaB: its consequences for strain typing schemes and population structures. *Epidemiol Infect*. 1995; 114(2): 257-266. doi: 10.1017/s0950268800057927.
4. Kuna L, Jakab J, Smolic R, Raguz-Lucic N, Vcev A, Smoli M. Peptic Ulcer Disease: A Brief Review of Conventional Therapy and Herbal Treatment Options. *J Clin Med*. 2019; 8(2): 179. doi: 10.3390/jcm8020179
5. Greenberg RE, Bank S. The prevalence of Helicobacter pylori in non-ulcer dyspepsia. *Arch. Intern Med*. 1990; 150: 2053-55. doi:10.1001/archinte.1990.00390210049012.
6. Berger A. Scientists discover how helicobacter survives gastric acid. *BMJ*. 2000; 320(7230): 268.
7. Das JC, Paul N. Epidemiology and pathophysiology of Helicobacter pylori infection in children. *Indian J Pediatr*. 2007; 74(3): 287-290. doi: 10.1007/s12098-007-0046-6.
8. Hasosah M. Accuracy of invasive and noninvasive methods of Helicobacter pylori infection diagnosis in Saudi children. *Saudi J Gastroenterol*. 2019; 25(2): 126-31. doi: 10.4103/sjg.SJG_288_18.
9. Al-Ezzy Al. Evaluation of Endoscopy based H. pylori Diagnostic Techniques in Iraqi Patients with upper Gastrointestinal Disorders. *Indian J Sci Technol*. 2016; 9(22): 1-10. DOI: 10.17485/ijst/2016/v9i22/85384.
10. Abadi ATB. Diagnosis of Helicobacter pylori Using Invasive and Noninvasive Approaches. *J Pathog*. 2018; 2018: 9064952. doi: 10.1155/2018/9064952.
11. Saxena A, Mukhopadhyay AK, Nandi SP. Helicobacter pylori: Perturbation and restoration of gut microbiome. *J Biosci*. 2020; 45(1): 110. doi: 10.1007/s12038-020-00078-7.
12. Lee A. Helicobacter pylori: causal agent in peptic ulcer, microbiological aspects. *Gastroenterol Hepatol*. 1991; 6(2): 115-120. doi: 10.1111/j.1440-1746.1991.tb01449.x.
13. Teh J, Shabbir A, Yuen S, Bok-Yan So J. Recent advances in diagnostic upper endoscopy. *World J Gastroenterol*. 2020; 26(4): 433-447. doi: 10.3748/wjg.v26.i4.433.
14. Moayyedi P, Lacy BE, Andrews CN, Enns RA, Howden CW, Vakil N. ACG and CAG Clinical Guideline: Management of Dyspepsia. *Am J Gastroenterol*. 2017; 112(7): 988-1013. doi: 10.1038/ajg.2017.154
15. Satti SA, Saeed F, Sarwar M. Comparison between serological testing and biopsy examination of helicobacter pylori. *Pak Armed Forces Med J*. 2004; 54(2): 195-8.
16. Tzeng JE, Lin YL, Chung SM, Chu YT. Comparison of four diagnostic method for Helicobacter pylori. *Tzu Chi Med J*. 2005; 17(5): 339-343.
17. Qureshi AF, Memon AS, Memon MA, Memon JM, Soomro AA, Shaikh MK. Incidence of Helicobacter pylori in gastroduodenitis. *Biomedica*. 1996; 12: 19-21.
18. Rotimi O, Cairns A, Gray S, Moayyedi P, Dixon MF. Histological identification of Helicobacter pylori comparison of staining methods. *J Clin Pathol*, 2000; 53(10): 756-9. doi: 10.1136/jcp.53.10.756.
19. Chisholm SA, Watson CL, Teare EL, Saverymuttu

S, Owen RJ. Noninvasive diagnosis of Helicobacter pylori infection in adult dyspeptic patients by stool antigen detection: does the rapid immunochromatography test provide a reliable alternative to conventional ELISA kit. J Med Biol. 2004; 53(Pt 7): 623-7.

20. Gisbert JP, Trepero M, Calvet X, Mendoza J,

Quesada M, Guell M et al. Evaluation of three different tests for the detection of stool antigens to diagnose Helicobacter pylori infection in patients with upper gastrointestinal bleeding. Aliment Pharmacol Ther. 2004; 19(8): 923-9. doi: 10.1111/j.1365-2036.2004.01932.x.



AUTHOR AFFILIATION:

Dr. Rasheed Ahmed Soomro

(Correspondence Author)

Associate Professor, Department of Pathology
Suleman Roshan Medical College
Tando Adam, Sindh-Pakistan.
Email: ralumhs@hotmail.com

Dr. Muhammad Kaleem

Assistant Professor, Department of Medicine
Suleman Roshan Medical College
Tando Adam, Sindh-Pakistan.

Dr. Riaz Ahmed Qazi

Professor of Pathology
Suleman Roshan Medical College
Tando Adam, Sindh-Pakistan.

Dr. Faisal Irshad

Associate Professor, Department of Pathology
Suleman Roshan Medical College
Tando Adam, Sindh-Pakistan.

Dr. Mehwish Zafar

Assistant Professor, Department of Pathology
Suleman Roshan Medical College
Tando Adam, Sindh-Pakistan.

Dr. Moin-ul-Islam

Assistant Professor, Department of Surgery
Suleman Roshan Medical College
Tando Adam, Sindh-Pakistan.



2022© This is an Open Access article distributed under the terms of the Creative Commons Attribution – Non-Commercial 4.0 International License, which permits unrestricted use, distribution & reproduction in any medium provided that the original work is cited properly.