

# Reconstruction of Soft Tissue Defects of Upper Extremity

Moez Fatima, Faisal Akhlaq Ali Khan

## ABSTRACT

**OBJECTIVE:** This study aims to evaluate the etiology of upper extremity soft tissue defects and determine the outcome of the various methods for covering upper limb soft tissue defects.

**METHODOLOGY:** This case series study was done at the Plastic and reconstructive Surgery department Civil Hospital, Karachi, from December 2018 to May 2019. Seventy-six cases were operated on in the department of plastic surgery. All patients with upper extremity defects with or without exposed bone, open fractures, and early presentation were included. Segmental bone defects, dirty wounds and patient's denial of consent were excluded. The mechanism of injury, association with fractures and the method of fixation was documented. Radiographic images were taken. Further, the functional and aesthetic outcome was assessed. Perfora data has been analyzed using SPSS 21.

**RESULTS:** The mean age of the patient was  $33 \pm 10.87$  years. Road traffic accidents 32.89% and machine cut injuries 31.58% were the commonest etiologies of upper limb defects. Postburn contracture was seen in 10.53%, secondary to debridement at 13.16%, secondary to fasciotomy at 3.95%, secondary to flap harvest at 6.58%, and secondary to tumor resection at 1.32%.

33(43.42%) upper limb defects were treated by grafting, and flaps were used in 43(56.58%).

**CONCLUSION:** Road traffic accidents and machine cut injuries are the main etiological factors of upper extremity defects. Grafting and flaps are used in the management of soft tissue defects. They have relatively low complication rates, provided that all measures should be taken to eliminate soft tissue or bone infection.

**KEYWORDS:** Soft tissue defect, Upper extremity defects, soft tissue coverage, Flaps for upper limb, Upper extremity reconstruction, Upper limb trauma.

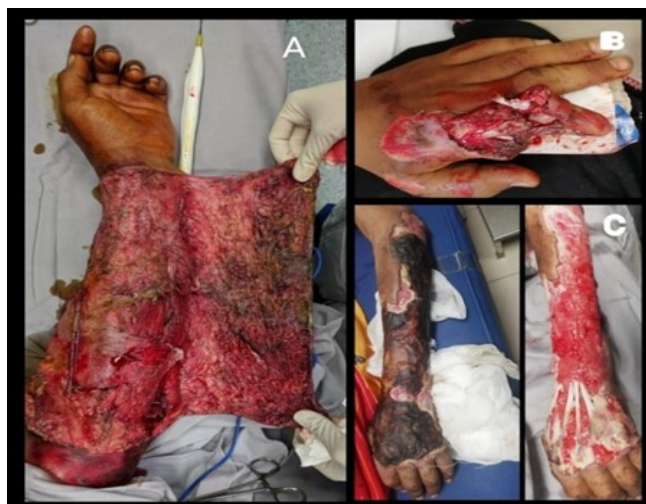*This article may be cited as:* Fatima M, Khan FAA. Reconstruction of Soft Tissue Defects of Upper Extremity. J Liaquat Uni Med Health Sci. 2022;21(04):258-63. doi: 10.22442/jlumhs.2022.00942.

## INTRODUCTION

Reconstruction of defects involving soft tissue of the upper limb is a common and imperative challenge<sup>1</sup>. Causes of upper limb defects include trauma due to road traffic accidents, machine injuries and wound dehiscence secondary to surgical treatment, abscesses, infections, necrotizing fasciitis, and tumor resection. Multiple approaches have evolved for mending and reconstructing these defects. Conservative treatment includes vacuum-assisted closure<sup>1</sup> or the dermal substitutive Integra (Integra Life Sciences, Plainsboro, N.J). Surgical options for treatment include skin grafts, local flaps, regional flaps<sup>2</sup>, distant flaps, fillet flaps<sup>3</sup> and free flaps<sup>4</sup>. **A picture 1** shows various etiologic factors causing soft tissues of the upper limb that will require definitive coverage.

As there are many modalities for management, we need to understand the reconstructive ladder and the choices we make for the upper limb critical raw area coverage. In conditions for a range of exposed bone or tendon, skin grafts would not be the option, as skin graft needs intact paratenon or periosteum. In these cases, local upper extremity flaps would be better options, like the V-Y advancement flap, Kutler flap,

**Picture 1: various etiologic factors causing soft tissues of the upper limb. A: road traffic accidents B: machine cut injury c: secondary to debridement after infection**



Atosay flap, Moberg flap, cross finger flap (standard, reverse), thenar flap, and Littler's neurovascular island flap. If the defect is significant and cannot be covered with local flaps, then regional flaps) are a reliable and safe method. They include the Radial forearm flap (standard, reverse)<sup>5</sup>, posterior interosseous artery flap

**Received:** 21-01-2022

**Revised:** 13-12-2022

**Accepted:** 22-12-2022

(standard, reverse)<sup>6</sup>, medial arm flap (standard, reverse), and lateral arm flap (standard, reverse). They are easy to perform, as planned and executed well, and have a low complication rate. Dual blood supply to the distal upper extremity allows the sacrifice of one major artery to raise the pedicle flap; when local and regional flaps are not possible, distant flaps and free tissue transfer can be used to reconstruct larger defects<sup>7-9</sup>. The meta-analysis by Ng ZY 2017<sup>10</sup> illustrated the management with negative pressure vacuum dressings on one end to the upper limb transplantation on the other end. Ding JP 2016<sup>11</sup> showed acceptable cosmetic and functional outcomes after six months of follow-up for 7x15 cm defects treated by pre-expanded pedicle flank flap.

## METHODOLOGY

This case series study was done at the Plastic and reconstructive Surgery department Civil Hospital, Karachi. The study was planned from December 2018 to May 2019. The total sample size was 76, selected by the Non-probability consecutive sampling technique using the WHO sample size calculator, taking statistics for machine cut injury as 20% (**based on pilot study Annexure I**) with the error margin of 0.09. The ages of 18 years to 60 years old comprised both genders.

Upper extremity defect with or without exposed bone, open fracture of upper extremity requiring soft tissue coverage, and patients presenting in the acute phase of injury (within four weeks) were included. Patients who had segmental bone defects and needed vascularized bone grafts, dirty wounds that needed multiple debridement sessions and denial of consent by the patients were excluded. Patients were admitted to the plastic surgery department from the emergency department, outpatient and referred from the

### APPENDIX A

Questionnaire: "Reconstruction of soft tissue defects of upper extremity."

Sr. No: \_\_\_\_\_ Date: \_\_\_\_\_  
 Name: \_\_\_\_\_ Reg. No: \_\_\_\_\_  
 Age: \_\_\_\_\_ Sex: Male Female  
 Mode of admission: OPD Emergency Referral

#### Co-morbidities:

None  Diabetes (HBA1C >7)  Hypertension (BP >150/90mmhg)  Other: \_\_\_\_\_

Smoker:  Yes  No

#### Mechanism of injury:

RTA  Machine cut injury  Tumor resection  Secondary defect after debridement  
 Other: \_\_\_\_\_

#### Size of wound:

Small  Medium  Large  Very Large

Associated Fracture:  Yes  No

#### Method of fracture fixation (if applicable):

ORIF  Ex-Fixation  Splintage

#### Type of coverage:

Graft  Local Flap  Regional Flap  Distant Flap  Free Flap  Flillet Flap

#### Complications of reconstruction:

None  Wound Infection

Graft Loss:  Complete graft loss  Incomplete graft Loss

Flap Necrosis:  Partial  Complete  Arterial Thrombosis  Venous Thrombosis

Need of second Procedure  Need of amputation

#### Complications of donor site:

None  Seroma  Wound Dehiscence  Sensory nerve dysfunction  Cellulitis

Hematoma

orthopaedics department involving upper extremity defects fulfilling the inclusion criteria. All these patients were included in the study after taking consent. Data collected were age, sex, size and site of the defect and cause of the defect, associated with or without bone fracture and fixation. Pre-existing co-morbidities like Hypertension, Diabetes mellitus, and Smoking habits were documented. The wound size was categorized as small, medium, large and very large based on percentage. The palm of the patient was equal to 1% of the total body surface area.

Basic investigations (total blood count) and pre-anaesthetic check-ups for fitness for surgery were done. X-rays of the injured limb were done to rule out fractured / osteomyelitis bone. A wound swab culture was sent. Once the wound was free of infection, coverage was planned.

No specific instrument was required, and the coverage was planned according to the defect dimension. The time between the injury and the wound coverage was noted, follow-up was done within four weeks, and the outcome was documented. Assessment of the Outcome was done regarding complications like wound infections (requiring debridement), partial or complete graft loss, partial or complete flap necrosis, and the need for secondary soft tissue coverage or amputation.

All the information was recorded on a Performa. Data were analyzed using IBM SPSS statistics for windows Version 21.0. Mean (S.D.) was computed for age, size and defect site. Frequency and percentage were calculated for gender, mode of admission, co-morbid (Diabetes mellitus, hypertension), smoking status, etiology, associated fracture type, type of coverage, and complications. Effect modifiers were controlled through stratification of age, gender, mode of admission, co-morbidities, and wound size. We applied a post-stratification Chi-square test, and P-value  $\leq 0.05$  was considered statistically significant.

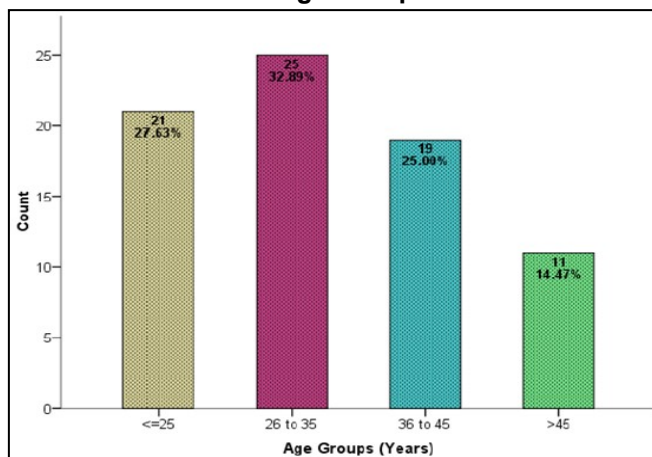
## RESULTS

Seventy-six patients with an open upper extremity fracture who required soft tissue coverage were included in this study. The age distribution of the patients is shown in **Figure I**. There were 62(81.58%) males and 14(18.42%) females from emergency. Diabetes Mellitus and Hypertension were observed in 13.16% and 14.47%, respectively. Out of 76 cases, 31 (40.76%) were smokers, and 13(17.11%) were associated with fractures. The aetiology of upper limb defects requiring soft tissue coverage is presented in **Figure II**. Road traffic accidents and machine cut injuries were the commonest cause of upper limb defects found in 32.89% and 31.58%, respectively. Post-burn contracture was seen in 10.53%, secondary to debridement at 13.16%, to fasciotomy at 3.95%, to flap harvest at 6.58% and secondary to tumour resection at 1.32%.

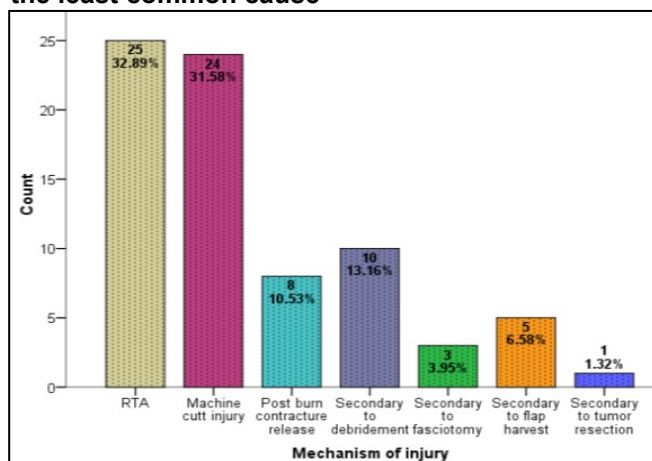
Out of 76 patients, 33(43.42%) with upper limb defects were treated with skin grafts, and 43(56.58 %) were covered with a flap, Out of which the split-thickness skin graft method was used in 27(35.53 %) and 6 (7.89%) full-thickness skin grafts. Regarding type of flaps, local flap was 17(22.37%), regional flap was 14 (18.42%), distal flap 8(10.53%), free flap 2(2.63%) and fillet flap was used in 2(2.63%) cases. As shown in **Figure III**.

Complications of methods used for covering up defects of the upper limb involving soft tissues are presented in the table. When skin grafts are used, the rate of wound infection and incomplete graft take was 24.2% (8/33). The hematoma and complete graft loss rates were in 2(6.1%) and 3 (9.1%) cases, respectively. In the donor site, the rate of wound dehiscence was 1(3.1%). Wound infection, hematoma, incomplete graft Loss, and complete graft loss were high in the split-thickness skin graft techniques (**Table I**).

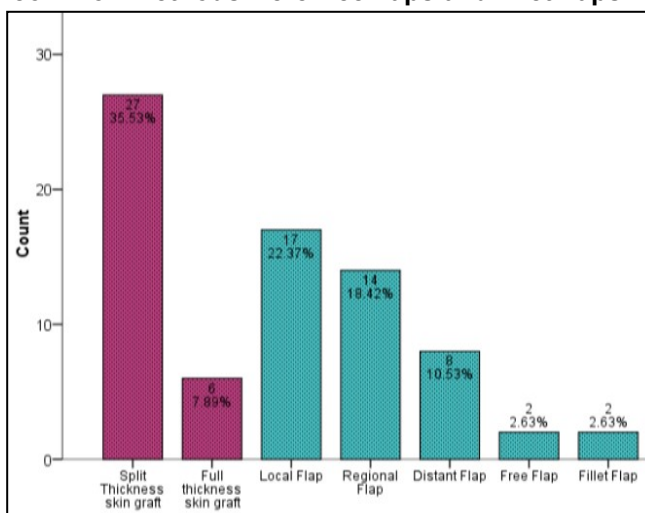
**Figure I: Bar Chart Illustrating Hand Trauma Incidence In Various Age Groups**



**Figure II: The bar chart illustrates that RTA was the most common cause of soft tissue defect in the upper limb, followed by machine cut injury, and defects secondary to tumor resection were the least common cause**



**Figure III: The bar chart illustrates that the most common coverage method was split-thickness skin graft, followed by local flaps. The least common methods were free flaps and fillet flaps**



**TABLE I: COMPLICATIONS OF GRAFTS METHOD FOR COVERAGE OF UPPER LIMB SOFT TISSUE**

Complications	Full Thickness Graft	Split Thickness Skin graft	Total n=33
	n=6	n=27	
<b>Reconstruction site</b>			
Wound infection	1	7	8
Hematoma	0	2	2
Incomplete Graft Loss	1	7	8
Complete Graft Loss	0	3	3
<b>Donor Site</b>			
Wound Dehiscence	1	0	1
Seroma	0	0	0
Cellulitis	0	0	0
Sensory Nerve Dysfunction	0	0	0

**DISCUSSION**

It's a demanding challenge for surgeons to cover defects involving soft tissues of the upper extremity due to trauma, infections, burns, or after tumor resections. The functional and aesthetic outcomes of the surgery are the net result of the quality of reconstructive procedures<sup>12</sup>. Various methods are recognized for reconstructing defects, either with grafts or flaps. Flaps can either be local, regional, or free flaps<sup>13</sup>. The most basic approach is preferable to provide robust coverage. Determination of the reconstructive procedure that will be used depends on factors like time and mechanism of injury, the extent of the site of injury, exposure of underlying tissues, and consequences if tissues are allowed to heal with



secondary intention<sup>14</sup>. Pre-requisites of a sturdy coverage are robust blood supply and defects free of contamination through debridement and removal of all necrotic tissues<sup>15,16</sup>. Restoration of soft tissue should be provided to avoid infections and allow patients to return to routine life early<sup>17,18</sup>.

Seventy-six patients who required upper extremity reconstruction were enrolled in this study. The study aimed to determine the causes of soft tissue defects in the upper extremity and

to evaluate the outcome of methods used for the coverage of these defects. These patients were predominantly young adults with an average age of 33.86±10.87 years, of the masculine gender (81.58%), people with diabetes (13.16%), smokers (40.76%), majority of injuries involved right (dominant) hand (78.9%). The demographic data in this study confirmed the study was done in a university hospital by Müller SS et al.<sup>19</sup>, who followed the series of open fractures. He also concluded that the study subjects were predominantly young men with a mean age of 35.2 years. A similar study by Moore TJ 1989<sup>20</sup> also suggested male predominance (78.85%) with a mean age of 31.

Trauma to the hand, wrist, elbow or arms can occur anywhere, like roads, work sites or even homes, leading to bone fractures, severe soft tissue injuries, and damage to tendons, ligaments and muscles. Our study concluded that major etiologic factors causing soft tissue defects were road traffic accidents (RTA) and machine cut injuries found in 32.89% and 31.58%, respectively. After the release of post-burn contractures, defects were seen at 10.53%, secondary to debridement at 13.16%, secondary to fasciotomy at 3.95%, secondary to flap harvest at 6.58 % and secondary to tumor resection at 1.32%. Bajaj HN 1988<sup>21</sup> reported that 28.9% of burns caused soft tissue defects, and 28.9% were affected by road traffic accidents. Vanderschot P 1995 found road traffic accidents a major etiologic factor in 21(67.7%) in a series of 31 fractures. A study by Jekic ML 1993<sup>23</sup> reported that 40 patients sustained trauma due to traffic accidents (63.4%).

Extensive details of flaps for elbow<sup>24</sup>, forearm<sup>25,26</sup>, fingers<sup>27,28</sup> and upper extremity<sup>29</sup> have been elaborated by various authors. Our study mentions all routinely performed flaps for almost all upper extremity regions. In our study, 33(43.42%) upper limb defects were treated by skin grafts, and flaps were used in 43 (56.58 %). Out of 76 patients, the split-thickness skin graft method was used in 27(35.53%) cases and 6 (7.89%) full-thickness skin grafts. Regarding type of flap, local flap was used in 17(22.37%), regional flap was 14(18.42%), distal flap 8(10.53%), free flap 2 (2.63%) and fillet flap was used in 2(2.63%) cases. Regarding the complication rate of the flap method in our study, the rate of wound infection was high, i.e. 23.3%, followed by Excessive flap Edema at 11.6% in

the reconstructed site. The rate of wound infection was high in local and distant flaps, while the rate of other complications was observed in regional flaps. The donor site rate of wound dehiscence and sensory nerve dysfunction was 23.3% and 11.6%, respectively; the study by Naalla R 2018<sup>13</sup> mentioned complications of flaps. The complications were marginal flap necrosis in 32 (15%) patients followed by partial flap necrosis in 15 (7%), infection in 11 (5%), wound dehiscence in 5 (2.4%) and total flap necrosis in 4 (2%) of patients. Marginal flap necrosis was managed conservatively, debridement was done for surgical site infections, resuturing was done for flap dehiscence after wound preparation, and either advancement of viable flap or addition of extra flap compensated partial flap loss. In contrast, a new strategy was designed to manage total flap necrosis.

There are multiple reasons for skin graft failure. Hematoma formation under the surface of the graft is the most common cause, as it prevents the graft from adhering to the wound bed and hence lack of blood supply leads to graft failure. A similar mechanism occurs when there is seroma formation leading to graft rejection. In our study, the complications of the method used to cover soft tissue defects by grafting method, wound infection rate, and incomplete graft loss were 24.2% (8/33) each, respectively. In the reconstructed site, the hematoma and complete graft loss rates were in 2(6.1%) and 3 (9.1%) cases. In the donor site, the rate of wound dehiscence was 3(9.1%). A study of 121 patients injured due to burns was conducted by Enshaei A 2014<sup>30</sup> They divided the groups into primary(early skin grafting ) and secondary (delayed skin grafting after resectioning burn wastes). All these patients underwent surgeries where grafting was done. A. Enshaei A 2014<sup>30</sup> reported that graft infection and rejection in the primary group was 3.7% and 2.1% in the secondary group, and they reported a 0% incidence of hematoma formation.

## CONCLUSION

In this study, we conclude that machine-inflicted injuries and road traffic accidents are the major etiologic factors of soft tissue defects of the upper extremity requiring coverage. Unforeseen circumstances can lead to accidents anywhere, anytime; these incidents can occur on the roads, workplaces, playgrounds, homes, or kitchens. They may result in complex bone fractures and severe soft tissue injuries involving tendons, ligaments, and muscles. The hand is the most complex appendage of the body and vital for everyday routine. Restoration of hand function is challenging and essential simultaneously for a good quality of life. Defects in soft tissue requiring coverage can be managed with grafting or flaps; both have proven safe with a reasonably low complication rate. Wound infection can

occur in both methods and is the most common complication, followed by hematoma. Before providing stable coverage, it is crucial to eradicate necrotic ischemic tissue and infection from the recipient site so that the wound bed is ready to accept the graft.

**Ethical permission:** Dow University of Health Sciences IRB letter No. IRB-1175/DUHS/Approval/2018, dated: 24-12-2018. CPSP – REU Dissertation approval letter No. CPSP/REU/PLS-2017-183-405, Dated 11-12-2019.

**Conflict of Interest:** No conflicts of interest, as stated by our authors.

**Financial Disclosure / Grant Approval:** No funding agency was involved in this research.

**Data Sharing Statement:** The corresponding author can provide the data proving the findings of this study on request. Privacy or ethical restrictions bound us from sharing the data publicly.

#### AUTHOR CONTRIBUTIONS

Fatima M: Article writing, data analysis

Khan FAA: Proof reading, supervision

#### REFERENCES

1. Niu XF, Yi JH, Zha GQ, Hu J, Liu YJ, Xiao LB. Vacuum sealing drainage as ampre-surgical adjunct in the treatment of complex (open) hand injuries: Report of 17 cases. *Orthop Traumatol Surg Res.* 2017; 103(3): 461-4. doi: 10.1016/j.otsr.2017.01.008. Epub 2017 Mar 6.
2. Das De S, Sebastin SJ. Considerations in Flap Selection for Soft Tissue Defects of the Hand. *Clin Plast Surg.* 2019; 46(3): 393-406. doi: 10.1016/j.cps.2019.03.010.
3. Masadeh S, Rodriguez P, Dierksheide AJ, Crisologo PA. Utility of the Digital Fillet Flap. *Clin Podiatr Med Surg.* 2020; 37(4): 775-787. doi: 10.1016/j.cpm.2020.07.009.
4. Zhang Y, Gazyakan E, Bigdeli AK, Will-Marks P, Kneser U, Hirche C. Soft tissue free flap for reconstruction of upper extremities: A meta-analysis on outcome and safety. *Microsurgery.* 2019; 39(5): 463-475. doi: 10.1002/micr.30460. Epub 2019 Apr 19.
5. Maan ZN, Legrand A, Long C, Chang JC. Reverse Radial Forearm Flap. *Plast Reconstr Surg Glob Open.* 2017; 5(4): e1287.
6. Eo SR, Hwang SH, Hong KY, Lim SA, Lee GJ. Revisiting the posterior interosseous artery flap. *Arch Hand Microsurg.* 2018; 23(3): 195-205.
7. Barin EZ, Cinal H, Kara M, Çakmak MA, Tan Ö. Versatile use of the posterior interosseous flap in the reconstruction of complex upper limb defects. *Ulus Travma Acil Cerrahi Derg.* 2019; 25(6): 597-602. doi: 10.14744/tjtes.2019.54889.
8. Adani R, Woo SH. Microsurgical thumb repair and reconstruction. *J Hand Surg Eur Vol.* 2017; 42(8): 771-788. doi: 10.1177/1753193417723310. Epub 2017 Aug 8.
9. Georgescu AV, Battiston B. Mangled upper extremity: Our strategy of reconstruction and clinical results. *Injury.* 2021; 52(12): 3588-604. doi: 10.1016/j.injury.2021.04.004.
10. Ng ZY, Tan SS, Lellouch AG, Cetrulo CL Jr, Chim HW. Soft Tissue Reconstruction of Complete Circumferential Defects of the Upper Extremity. *Arch Plast Surg.* 2017; 44(2):117-23. doi: 10.5999/aps.2017.44.2.117.
11. Ding JP, Chen B, Fang L, Wang LZ. Total reconstruction of giant congenital circumferential nevi of the upper limb using a large pedicle expanded flank flap: a brief report. *Ann R Coll Surg Engl.* 2016; 98: e150-51. doi: 10.1308/rcsann.2016.0195.
12. De SD, Sebastin SJ. Considerations in flap selection for soft tissue defects of the hand. *Clin Plast Surg.* 2019; 46(3): 393-406. doi: 10.1016/j.cps.2019.03.010.
13. Naalla R, Chauhan S, Dave A, Singhal M. Reconstruction of post-traumatic upper extremity soft tissue defects with pedicled flaps: An algorithmic approach to clinical decision making. *Chin J Traumatol.* 2018; 21(06): 338-51. doi: 10.1016/j.cjtee.2018.04.005.
14. Bumbasirevic M, Stevanovic M, Lesic A, Atkinson HD. Current management of the mangled upper extremity. *Int Orthop.* 2012; 36(11): 2189-95. doi: 10.1007/s00264-012-1638-y. Epub 2012 Aug 25.
15. Steed DL. Debridement. *Am J Surg.* 2004; 187(5): 71S-74S. doi: 10.1016/S0002-9610(03)00307-6.
16. De Francesco F, Marchesini A, Campodonico A, Neuendorf AD, Pangrazi PP, Riccio M. A multistep iter for functional reconstruction in mangled upper limb: A retrospective analysis of integrated surgical and medical approach. *Medicina (Kaunas).* 2020; 56(8): 398. doi: 10.3390/medicina56080398.
17. Qiu E, Kurlander DE, Ghaznavi AM. Godina revisited: a systematic review of traumatic lower extremity wound reconstruction timing. *J Plast Surg Hand Surg.* 2018; 52(5): 259-64. doi: 10.1080/2000656X.2018.1470979. Epub 2018 Jul 2.
18. Herter F, Ninkovic M, Ninkovic M. Rational flap selection and timing for coverage of complex upper extremity trauma. *J Plast Reconstr Aesthet Surg.* 2007; 60(7): 760-8. doi: 10.1016/j.bjps.2007.03.008. Epub 2007 May 29.
19. Müller SS, Sadenberg T, Pereira GJ, Sadatsune T, Kimura EE, NovelliFilho JL. Epidemiological, clinical and micorbiological prospective study of patients with open fractures assisted at a university hospital. *Acta Ortop Bras.* 2003;11: 158-69.
20. Moore TJ, Mauney C, Barron J. The use of

- quantitative bacterial counts in open fractures. Clin Orthop Relat Res. 1989; (248): 227-230.
21. Bajaj HN, Rao PS, Kumar B, Chacho V. Subtrochanteric fractures of femur an analysis of operative and non-operative management. Injury. 1988; 19(3): 169-71. doi: 10.1016/0020-1383(88)90008-3.
  22. Vanderschot P, Vanderspeeten K, Verheyen L, Broos P. A review on 161 subtrochanteric fractures--risk factors influencing outcome: age, fracture pattern and fracture level. Unfallchirurg. 1995; 98(5): 265-71.
  23. Jekic ML, Jekic IM. Primary management and problem with osteosynthesis of subtrochanteric fractures of femur. Halv Chir Acta 1993; 59(4): 533-5.
  24. Gandolfi S, Auquit-Auckbur I, Poirot Y, Bonmarchand A, Mouton J, Carloni R et al. Focus on anatomical aspects of soft tissue coverage options in elbow reconstruction: an updating review. Surg Radiol Anat. 2018; 40(8): 943-54. doi: 10.1007/s00276-018-2066-5. Epub 2018 Jul 10.
  25. Wagner RD, Carr L, Netscher DT. Current indications for abdominal-based flaps in hand and forearm reconstruction. Injury. 2020; 51(12): 2916-21. doi: 10.1016/j.injury.2020.02.105. Epub 2020 Feb 21.
  26. Acharya AM, Ravikiran N, Jayakrishnan KN, Bhat AK. The role of pedicled abdominal flaps in hand and forearm composite tissue injuries: Results of technical refinements for safe harvest. J Orthop. 2019; 16(4): 369-76. doi: 10.1016/j.jor.2019.04.008.
  27. Elliot D, Adani R, Hyun Woo S, Tang JB. Repair of soft tissue defects in finger, thumb and forearm: less invasive methods with similar outcomes. J Hand Surg Eur Vol. 2018; 43(10): 1019-29. doi: 10.1177/1753193418805698.
  28. Tang JB. Fingertip repair methods: choices for different fingers and sides emphasizing sensation. J Hand Surg Eur Vol. 2019; 44(10): 1109-11. doi: 10.1177/1753193419876496. Epub 2019 Sep 26.
  29. Benanti E, De Santis G, Acciaro AL, Colzani G, Baccarani A, Starnoni M. Soft tissue coverage of the upper limb: A flap reconstruction overview. Ann Med Surg. 2020; 60: 338-43. doi: 10.1016/j.amsu.2020.10.069.
  30. Enshaei A, Masoudi N. Survey of Early Complications of Primary Skin Graft and Secondary Skin Graft (Delayed) Surgery after Resection of Burnwaste in Hospitalized Burn Patients. Glob J Health Sci. 2014; 6(7 Spec No): 98-102. doi: 10.5539/gjhs.v6n7p98.



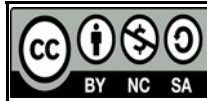*AUTHOR AFFILIATION:*

**Dr. Moez Fatima** (*Corresponding Author*)

Fellow, Department of Plastic & Reconstructive Surgery  
Dow University of Health Sciences &  
Dr. Ruth KM Pfau Civil Hospital  
Karachi, Sindh-Pakistan.  
Email: dr.moezfatima@outlook.com

**Dr. Faisal Akhlaq Ali Khan**

Professor, Department of Plastic & Reconstructive Surgery  
Dow University of Health Sciences &  
Dr. Ruth KM Pfau Civil Hospital  
Karachi, Sindh-Pakistan.



2022 © This is an Open Access article distributed under the terms of the Creative Commons Attribution – Non-Commercial 4.0 International License, which permits unrestricted use, distribution & reproduction in any medium provided that the original work is cited properly.