

Clinical and Functional Outcomes of Arthroscopic Bankart Repair among Patients with Recurrent Anterior Shoulder Dislocation

Naveed Ali Shair^{1*}, Muhammad Abubakar², Rehan Sittar², Muhammad Khalid Syed³,
Abdullah Tariq⁴, Muhammad Hanif Mian³

ABSTRACT

OBJECTIVE: To note the functional outcome of recurrent anterior shoulder dislocation with Bankart repair (BR) treated with arthroscopic stabilisation with suture anchors.

METHODOLOGY: This prospective cohort study was conducted at the Department of Orthopedic Surgery, Lahore General Hospital, Lahore, from January 2021 to June 2022. Patients undergoing arthroscopic BR with anterior instability of the glenohumeral joint with at least >6 episodes of dislocation/subluxation in the last six months were analysed. Functional outcomes were assessed at one-month, three-month and six month intervals post-surgery using "Modified University of California Los Angeles (UCLA)" and "Simple Shoulder Test (SST)".

RESULTS: Of 25 patients, 24 (96.0%) were male. The mean age was 27.20±4.0 years. The mean duration of symptoms was 9.1±6.2 months. In 16 (64.0%) patients, 2-suture anchors were utilised, while 3-suture anchors were used in the remaining 9 (36.0%) patients. Pre-surgery, the mean UCLA score was 16.4±5.6 and improved to 1-month, 3-month and 6-month as 16.6±5.1, 22.8±6.2 and 28.4±6.6 respectively (p<0.001). Pre-surgery, the mean SST score was 4.7±2.4 which improved to 1-month, 3-month and 6-month as 5.4±2.6, 8.1±3.3 and 11.2±3.1 respectively (p<0.001). All patients (100%) had full range of motion after six months post-surgery.

CONCLUSION: Arthroscopic BR in recurrent anterior shoulder dislocation was a reliable procedure regarding functional outcomes and range of motion after six months of follow-up.

KEYWORDS: Arthroscopy, Bankart repair, shoulder dislocation, suture anchors, range of motion.

INTRODUCTION

Glenohumeral joint dislocation is a frequently occurring condition which constitutes a significant portion of all joint dislocations, and the incidence of anterior dislocation is more common¹. Glenoid is a less acute cavity connected with only a minor portion of the head of the humerus to cause instability of the shoulder joint². The recurrence of the dislocation of the shoulder joint makes anterior glenohumeral dislocation more complicated; among patients 20-40 years of age, it has recurrence rates between 70-90%

The anterior dislocation can occur due to unnatural abduction and outward shoulder rotation, bringing instability in the joint⁴. In the early 20th century, Perthes and Bankart noted that the glenoid rim

released the anterior inferior labrum^{5,6}. In more than 80% of the shoulder joints having recurrent shoulder instability, Bankart lesion shows its presence⁷. As time passes and with active proceedings, dislocation occurs at an increasing frequency, and only one repetition of dislocation is labeled as recurrence.

Considering treatment options for recurrent shoulder dislocations, open Bankart repair (BR) is regarded as a standard procedure that re-establishes the anatomical structure of the shoulder joint very close to the normal⁸. Through this technique, recurrent instability rates are merely 7% on average⁹. Regarding anterior glenohumeral instability, these results are remarkable, but arthroscopic management has been of great interest because of the associated benefits^{10,11}. This research was carried out to note the clinical and functional outcomes of arthroscopic Bankart repair (BR) among patients with recurrent anterior shoulder dislocation.

METHODOLOGY

This prospective cohort study was conducted at the Department of Orthopedic Surgery, Lahore General Hospital, Lahore, from January 2021 to June 2022. Approval from "Institutional Review Board" was acquired (letter number: 965/02). Written and informed consent were taken from all study participants. Patients of either gender, aged 18 to 50 years,

*¹Department of Orthopedic Surgery, Lahore General Hospital, Lahore, Punjab-Pakistan.

²Department of Orthopedics, Sir Ganga Ram Hospital/ FJMU, Lahore, Punjab-Pakistan.

³Department of Orthopedic and Spine Surgery, Lahore General Hospital, Lahore, Punjab-Pakistan.

⁴Department of Orthopedic Surgery, DHQ Hospital, Nanakana Sahab, Lahore, Punjab-Pakistan.

Correspondence: dr_malik912@yahoo.com
doi: 10.22442/jlumhs.2023.01029

Received: 28-03-2023 Accepted: 13-07-2023
Published Online: 21-09-2023



undergoing arthroscopic BR with anterior glenohumeral joint instability and > six episodes of dislocation/subluxation in the last six months were included. All cases had positive clinical apprehension tests and radiological evidence (instability and bone loss < 25%). Patients who were contact sports athletes, previously failed arthroscopy or open surgery, had a history of seizures, and multidirectional instability/habitual dislocation were excluded. Standard surgical techniques were adopted. Functional outcome and recurrence were evaluated at one month, three months, and six months post-surgery using Modified "University of California Los Angeles (UCLA)" and "simple shoulder test (SST)". Statistical Package for Social Sciences (SPSS) version 26.0 was employed for data analysis. For the description of qualitative variables, frequency and percentages were shown. Mean and standard deviations (SD) were calculated to describe quantitative data. Functional outcomes in terms of UCLA and SST scores were compared using "Analysis of variance (ANOVA)", taking $p < 0.05$ as significant.

RESULTS

Of 25 patients, 24 (96.0%) were male, while the mean age was 27.20 ± 4.0 years. Involvement of the right shoulder was noted in 16 (64.0%) cases. Pain and discomfort were recorded by 12 (48.0%) and 5 (20.0%) patients respectively. The mean duration of symptoms was 9.1 ± 6.2 months. In 16 (64.0%) patients, 2-suture anchors were utilised, while 3-suture anchors were used in the remaining 9 (36.0%) patients. **Table I** shows details of the demographical and clinical characteristics of the patients studied. In 16 (64.0%) patients, 2-suture anchors were utilised, while 3-suture anchors were used in the remaining 9 (36.0%) patients. **Figure I** shows pre-operative and intra-operative figures.

Pre-surgery, the mean UCLA score was 16.4 ± 5.6 , and it improved to 1-month, 3-month and 6-month as 16.6 ± 5.1 , 22.8 ± 6.2 and 28.4 ± 6.6 respectively ($p < 0.001$) as shown in **Figure II**. Pre-surgery, the mean SST score was 4.7 ± 2.4 which improved to 1-month, 3-month and 6-month as 5.4 ± 2.6 , 8.1 ± 3.3 and 11.2 ± 3.1 respectively ($p < 0.001$) as shown in **Figure III**.

After six months post-surgically, all (100%) cases achieved full range of motion in all planes. No patients reported apprehension in the follow-up period of 6 months. None of the cases had a recurrence of dislocation/subluxation or stiffness at the follow-up period's end. All cases returned to their normal daily life activities at six months post-surgically. Eighteen patients (72.0%) returned to previous sporting activities by the end of 6 months, while the remaining 7 (28.0%) feared a recurrence.

Table I: Demographics and Clinical Characteristics of Patients (n=25)

Characteristics	Frequency(%)
Gender	Male 24 (96.0%)
	Female 1 (4.0%)
Age (years)	18-30 17 (68.0%)
	31-50 8 (32.0%)
Side involved	Right 16 (64.0%)
	Left 9 (36.0%)
Affected shoulder stability	Unstable 18 (72.0%)
	Stable 7 (28.0%)
Pain/Comfort	Discomfort 5 (20.0%)
	Pain 12 (48.0%)
	No pain 8 (32.0%)
Duration of symptoms (year)	≤ 1 17 (68.0%)
	> 1 8 (32.0%)
Past history of dislocations	7-10 time 23 (92.0%)
	> 10 times 2 (8.0%)

Figure I: Pre-operative and intra-operative images

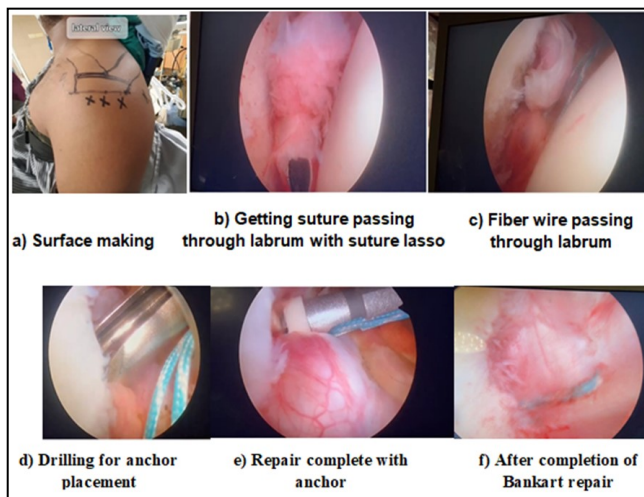


Figure II: Comparison of pre-surgery and post-surgery follow-up UCLA scores (n=25)

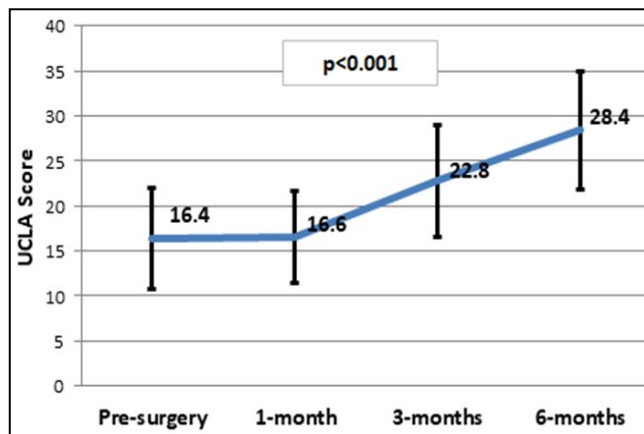
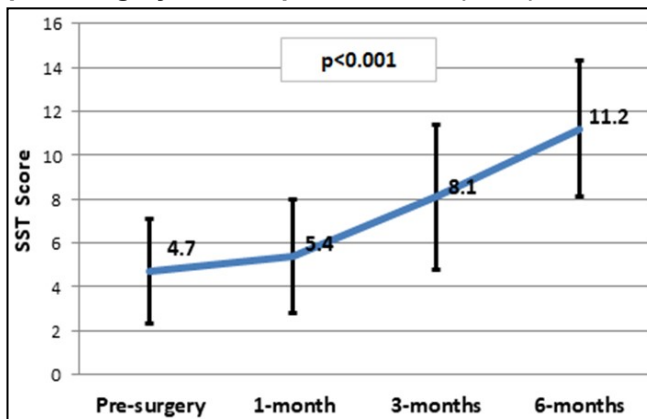


Figure III: Comparison of pre-surgery and post-surgery follow-up SST scores (n=25)



DISCUSSION

For the first time in 1957, Dickson and Devas published the results (derived by Bankart himself) of open repair of the anterior instability of the shoulder with a glenoid labrum tear¹². Shoulder arthroscopy was a limited diagnostic modality in the past. Still, within the last 20 years, it evolved into a surgical technique. It reported varying success using different stabilising techniques¹³. Arthroscopic management is developing into a preferable choice for anterior glenohumeral instability as it causes less morbidity, needs shorter time to complete the surgery, improves the range of motion, improves cosmesis, and causes less pain after surgery¹⁴.

In 64% of our study cases, we used 2-suture anchors, whereas the other 36% were managed using 3-suture anchors. Contrary to our findings, Pascal Boileau et al.¹⁵ used four anchor points that provided substantial shoulder stabilisation. Not a single patient in this study reported a complaint of pain, lack of stability or uneasiness similar to what others described in the past^{16,17}. Before surgery, the mean UCLA score of our study cases was 16.4 ± 5.6 , which improved up to 28.4 ± 6.6 after six months of the surgery. UCLA was among the initial scoring systems to measure the shoulder outcome, so we used it. Its easy administration and the capacity to rapidly evaluate the results for a wide range of diagnoses have made it helpful to clinicians to have low inter-observer variability. A study by Kumar et al.¹⁸ reported the mean pre-surgery UCLA score as 18, which improved to 31.8 after 12 months of follow-up following arthroscopic BR in patients with recurrent anterior shoulder dislocations.

After six months of surgery, an improvement in the SST score with a mean of 11.2 ± 3.1 was observed against an SST score of 4.7 ± 2.4 calculated before surgery. "American Shoulder and Elbow Surgeons" have also endorsed SST for the assessment of shoulder function, and it has been in their recommendations¹⁹. A study by Ee GW et al.²⁰ included 74 patients of traumatic anterior shoulder

instability collected in a single hospital over four years. They analysed the long-term results of arthroscopic BR. The research revealed that in 45.9% of patients, excellent outcome was observed, whereas in 47.3% of patients, results were good and fair in 1.4%, while 4.1% had poor outcomes. They established that by using a suture anchor, arthroscopic BR was a consistent treatment procedure, having satisfactory clinical outcome, outstanding postoperative movement of the shoulder and less frequency of recurrence per our findings²⁰. In a meta-analysis performed by Hobby et al.²¹, 62 studies, which included 3044 arthroscopic surgeries, were reviewed systematically, and it was concluded that arthroscopic stabilisation using suture anchors and bio-absorbable tacs had lower rates of failure in comparison to staples and transglenoid sutures. Moreover, similar failure rates have been linked with arthroscopic anterior stabilisation and open stabilisation after a follow-up of 2 years²¹.

As this was a single-centre study with a relatively small follow-up period (6 months), our findings need further verification in multicentric studies on significant follow-up duration. Nonetheless, the present study adds essential insights to our experience of Bankart repair among those patients who have recurrent shoulder dislocation from a tertiary healthcare facility in a developing country.

CONCLUSION

Arthroscopic BR in recurrent anterior shoulder dislocation was found to be a reliable procedure regarding functional outcomes, range of motion and recurrence aspects on assessment after six months of follow-up.

Ethical permission: Lahore General Hospital, Lahore, IRB letter No. 965/02.

Conflict Of Interest: No conflicts of interest, as stated by authors.

Financial Disclosure / Grant Approval: No funding agency was involved in this research.

Data Sharing Statement: The corresponding author can provide the data proving the findings of this study on request. Privacy or ethical restrictions bound us from sharing the data publically.

AUTHOR CONTRIBUTIONS

Shair NA: Substantial contributions to the conception of the work

Abubakar M: Substantial contributions to the design of the work

Sittar R: Drafting and revising the work for important intellectual content

Syed MK: Acquisition, analysis, or interpretation of data for the work

Tariq A: Substantial contributions to the conception of the work

Mian MH: Final approval of the version of this manuscript

REFERENCES

1. Cutts S, Prempeh M, Drew S. Anterior shoulder dislocation. *Ann R Coll Surg Engl.* 2009; 91(1): 2-7. doi:10.1308/003588409X359123.
2. Griffith JF. Measuring glenoid and humeral bone loss in shoulder dislocation. *Quant Imaging Med Surg.* 2019; 9(2): 134-143. doi:10.21037/qims.2019.01.06.
3. Adla DN, Shukla S, Pandey R. Clinical outcome of arthroscopic anterior stabilisation of shoulder using absorbable knotless suture anchors. *J Bone Joint Surg Br.* 2009; 91-B(Suppl-1): 118. doi:10.1302/0301-620X.91BSUPP_I.0910118b.
4. Taylor D, Arciero R. Pathologic changes associated with shoulder dislocations. Arthroscopic and physical examination findings in first-time, traumatic anterior dislocations. *Am J Sports Med.* 1997; 25(3): 306-311. doi: 10.1177/036354659702500306.
5. Perthes G. Über Operationen bei habitueller Schulterluxation. *Dtsch Z Chir* 1906; 56: 149-151.
6. Bankart ASB. Recurrent or habitual dislocation of the shoulder. *BMJ.* 1920; 1: 1132-1133.
7. White AE, Patel NK, Hadley CJ, Dodson CC. An Algorithmic Approach to the Management of Shoulder Instability. *J Am Acad Orthop Surg Glob Res Rev.* 2019; 3(12): e19.00168. doi:10.5435/JAAOSGlobal-D-19-00168.
8. Moya D, Aydin N, Yamamoto N. Current concepts in anterior glenohumeral instability: diagnosis and treatment. *SICOT J.* 2021; 7: 48. doi: 10.1051/sicotj/2021048.
9. Freedman KB, Smith AP, Romeo AA, Cole BJ, Bach BR Jr. Open Bankart repair versus arthroscopic repair with transglenoid sutures or bioabsorbable tacks for Recurrent Anterior instability of the shoulder: a meta-analysis. *Am J Sports Med.* 2004; 32(6): 1520-1527. doi:10.1177/0363546504265188.
10. Mousavibaygei SR, Moein S, Sharifi Razavi D, Haghi F, Karimi Matloub R. Evaluating the results of Bankart repair in recurrent traumatic anterior shoulder dislocation. *Int J Burns Trauma.* 2021; 11(4): 337-343.
11. Amroodi MN, Jafari D, Kousari AA. Results of Open Bankart Surgery for Recurrent Anterior Shoulder Dislocation with Glenoid Bone Defect and Concomitant Hill-Sachs Lesion. *Arch Bone Jt Surg.* 2018; 6(3): 212-218.
12. Dickson JW, Devas MB. Bankart's operation for recurrent dislocation of shoulder. *J Bone Joint Surg (Br).* 1957; 39: 114-9.
13. Moore ML, Pollock JR, McQuivey KS, Bingham JS. The Top 50 Most-Cited Shoulder Arthroscopy Studies. *Arthrosc Sports Med Rehabil.* 2021; 3(1): e277-e287. doi:10.1016/j.asmr.2020.09.011.
14. Vaishya R. The rise of shoulder arthroscopy. *J Clin Orthop Trauma.* 2019; 10(2): 221. doi: 10.1016/j.jcot.2019.02.003.
15. Boileau P, Villalba M, Héry JY, Balg F, Ahrens P, Neyton L. Risk factors for recurrence of shoulder instability after arthroscopic Bankart repair. *J Bone Joint Surg Am.* 2006; 88(8): 1755-1763. doi: 10.2106/JBJS.E.00817.
16. Yadav YK. Recurrent anterior shoulder instability. *Med J Armed Forces India.* 2002; 58(1): 95-96. doi: 10.1016/S0377-1237(02)80033-8.
17. Bonazza NA, Riboh JC. Management of recurrent anterior shoulder instability after surgical stabilisation in children and adolescents. *Curr Rev Musculoskelet Med.* 2020; 13(2): 164-172. doi: 10.1007/s12178-020-09612-4.
18. Kumar R, Rashid R, Kumar K, Vishwanath MS. The clinical and functional outcome of arthroscopic bankart repair in recurrent shoulder dislocation. *Int J Orthopaed Sci.* 2021; 7(1): 147-151.
19. Minoughan CE, Schumaier AP, Fritch JL, Grawe BM. Correlation of Patient-Reported Outcome Measurement Information System Physical Function Upper Extremity Computer Adaptive Testing, with the American Shoulder and Elbow Surgeons Shoulder Assessment form and Simple Shoulder Test in Patients with Shoulder Pain. *Arthroscopy.* 2018; 34(5): 1430-1436. doi: 10.1016/j.arthro.2017.11.040.
20. Ee GW, Mohamed S, Tan AH. Long-term results of arthroscopic Bankart repair for traumatic anterior shoulder instability. *J Orthop Surg Res.* 2011; 6: 28. doi: 10.1186/1749-799X-6-28.
21. Hobby J, Griffin D, Dunbar M, Boileau P. Is arthroscopic surgery for stabilisation of chronic shoulder instability as effective as open surgery? A systematic review and meta-analysis of 62 studies including 3044 arthroscopic operations. *J Bone Joint Surg Br.* 2007; 89(9): 1188-1196. doi: 10.1302/0301-620X.89B9.18467.

